

# TASC D Registry

12-month effectiveness analysis of the Pulsar™-18 self-expanding nitinol stent in patients with Critical Limb Ischemia (CLI)<sup>1</sup>

## Conclusions

- Superficial Femoral Artery (SFA) TASC D lesions can be treated with the Pulsar™ stent with 100 % procedural success in CLI patients
- The Average Lesion Length (A.L.L) of 24.5 cm is much longer than other published data<sup>\*\*\*</sup> while Primary Patency (PP)<sup>\*</sup> and Freedom from Target Lesion Revascularization (FTLR) rates are similar to this published data<sup>2</sup>
- In these very long and chronic total occluded lesions the Pulsar™ stents provide sufficient radial force shown by the 77 % PP at 12 months

### Study design

Single center, observational study.

### Endpoints

- PP\* at 6 and 12 months
- FTLR

### Patient characteristics

		N=22
Average age, yrs		73.8
Male	9	40.9 %
Hypertension	16	72.7 %
Dyslipidemia	18	81.6 %
Current smoker	10	45.5 %
Diabetes mellitus	16	72.7 %
Adipositas	15	68.2 %
Renal insufficiency	18	81.8 %
Rutherford classification 4	17	77.3 %
Rutherford classification 5	5	22.7 %
Ankle-brachial index (ABI)**		0.44±0.18

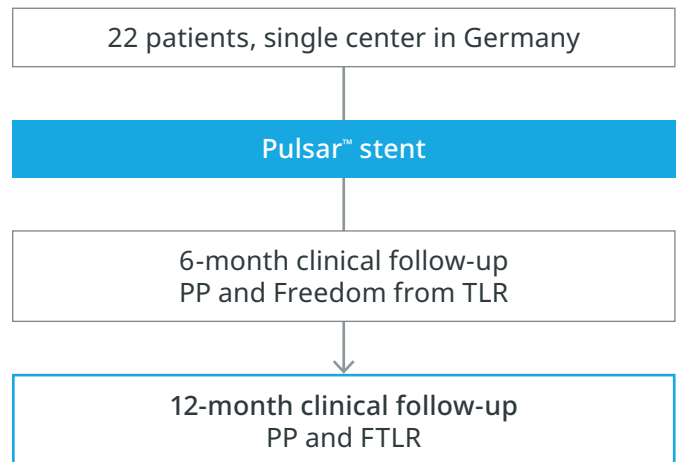
### Lesion characteristics

		n=22
A.L.L (mm)		245
Minimal length (mm)		215
Maximal length (mm)		315
TASC D lesion with chronic total occlusion >20 cm		22/22
>1 patent crural vessel		22/22
Endovascular success with straight line to the forefoot		22/22

\* Restenosis (>50%) on duplex ultrasound

\*\* Data shown as mean±SD

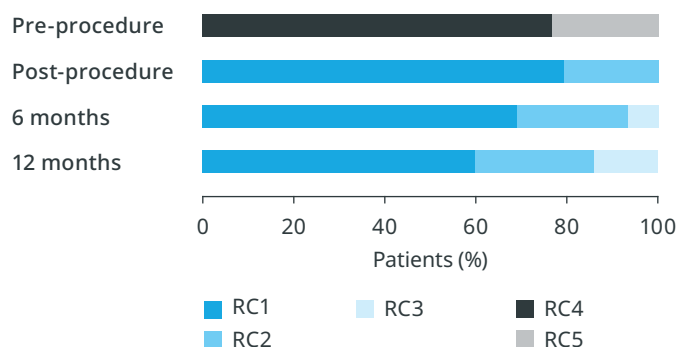
\*\*\* Check table on the next page with the 12-month clinical results by A.L.L



### Results

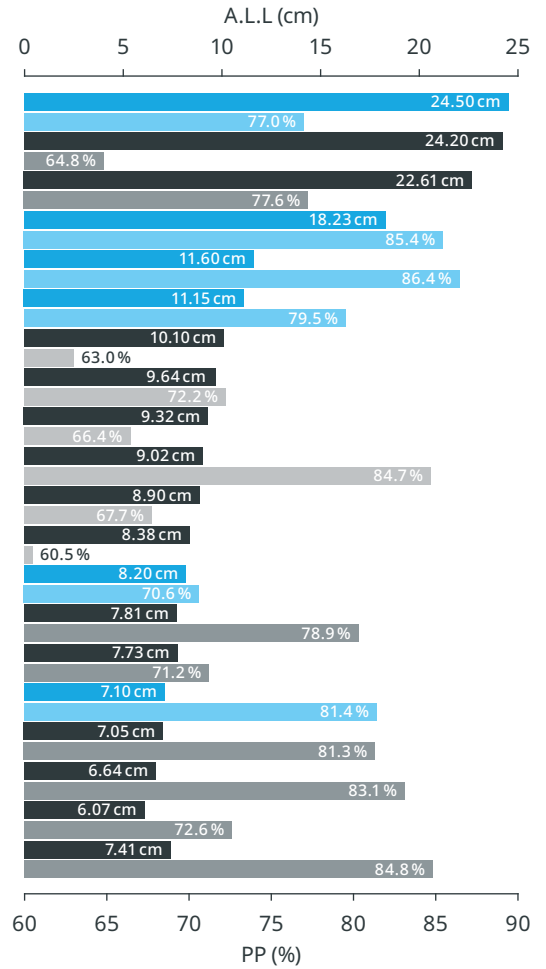
	6 MONTHS	12 MONTHS
PP	86.0 %	77.0 %
FTLR	91.0 %	86.0 %
ABI**	0.88±0.2	0.85±0.2

### Rutherford Classification (RC) changes

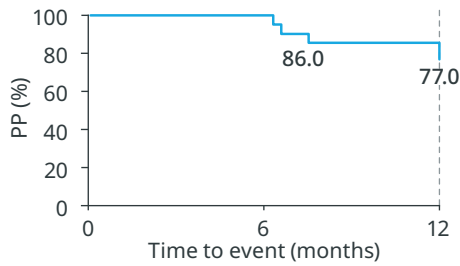


## 12-month clinical results by A.L.L

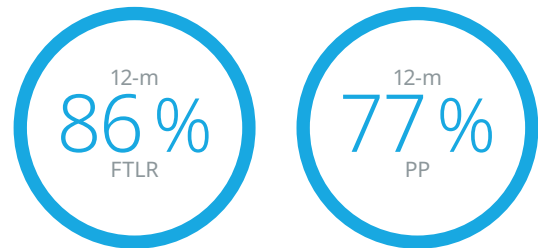
STUDY	PRODUCT	PP	TLR	A.L.L
<b>TASC D<sup>1</sup></b>	<b>Pulsar™</b>	<b>77.0%</b>	<b>14.0%</b>	<b>24.50 cm</b>
DURABILITY 200 <sup>2</sup>	EverFlex	64.8%	31.8%	24.20 cm
ZILVER PTX LONG <sup>3</sup>	Zilver PTX	77.6%	14.6%	22.61 cm
<b>TASC D II<sup>4</sup></b>	<b>Pulsar™</b>	<b>85.4%</b>	<b>12.5%</b>	<b>18.23 cm</b>
<b>BIOFLEX PEACE5</b>	<b>Pulsar™</b>	<b>86.4%</b>	<b>2.9%</b>	<b>11.60 cm</b>
<b>PEACE<sup>6</sup></b>	<b>Pulsar™</b>	<b>79.5%</b>	<b>19.0%</b>	<b>11.15 cm</b>
ABSOLUTE <sup>7</sup>	Absolute	63.0%	n/a	10.10 cm
DURABILITY <sup>8</sup>	EverFlex	72.2%	20.9%	9.64 cm
SuperNOVA <sup>9</sup>	Innova	66.4%	14.2%	9.32 cm
SUPERA <sup>10</sup>	Supera	84.7%	n/a	9.02 cm
DURABILITY II <sup>11</sup>	EverFlex	67.7%	13.9%	8.90 cm
OSPREY <sup>12</sup>	Misago	60.5%	13.0%	8.38 cm
<b>BIOFLEX-I<sup>13</sup></b>	<b>Pulsar™</b>	<b>70.6%</b>	<b>12.4%</b>	<b>8.20 cm</b>
SUPERB <sup>14</sup>	Supera	78.9%	11.1%	7.81 cm
STROLL <sup>15</sup>	S.M.A.R.T. Control	71.2%	12.3%	7.73 cm
<b>4EVER<sup>16</sup></b>	<b>Pulsar™</b>	<b>81.4%</b>	<b>10.7%</b>	<b>7.10 cm</b>
RESILIENT <sup>17</sup>	Lifestent	81.3%	12.7%	7.05 cm
ZILVER PTX <sup>18</sup>	Zilver PTX	83.1%	9.5%	6.64 cm
COMPLETE SE <sup>19</sup>	Complete SE	72.6%	9.4%	6.07 cm
MISAGO 2 <sup>20</sup>	Misago	84.8%	10.8%	7.41 cm



## 12-month PP



## Key outcomes



**Principal investigator:** Dr. Michael Lichtenberg, Klinikum Arnsberg, Germany

**References:**

- 1 Lichtenberg M et al. Superficial femoral artery TASC D Registry: twelve-month effectiveness analysis of the Pulsar-18 SE nitinol stent in patients with critical limb ischemia. *J Cardiovasc Surg.* 2013;54(4):433-9.
- 2 Bosiers M et al. Results of the Protégé EverFlex 200-mm-long nitinol stent (ev3) in TASC C and D femoropopliteal lesions (DURABILITY 200), *J Vasc Surg.* 2011;54(4):1042-50.
- 3 Bosiers M et al. The Zilver PTX Single Arm Study: 12-month results from the TASC C/D lesion subgroup, *J Cardiovasc Surg* 2013;54:115-22. NCT00120406.
- 4 Lichtenberg M et al. TASC D II, Evaluation of the 4-French Pulsar-18 Self-expanding Nitinol Stent in Long Femoropopliteal Lesions. *Clinical Medicine Insights: Cardiology* 2014;8(S2) 37-42.
- 5 Lichtenberg M. BIOFLEX PEACE Registry 12 & 24 month results. Presented at: LINC; 2018; Leipzig, Germany.
- 6 Lichtenberg M et al. PEACE I All-Comers Registry: Patency Evaluation After Implantation of 4-French Pulsar-18 SE Nitinol Stent in Femoropopliteal Lesions. *J ENDOVASC THER.* 2014; 21: 373-380.
- 7 Schillinger et al. ABSOLUTE, 12-month results: *N Engl J Med* 2006;354:1879-88.
- 8 Bosiers M, Nitinol Stent Implantation in Long Superficial Femoral Artery Lesions: 12-Month Results of the DURABILITY I Study. *J ENDOVASC THER* 2009;16:261 -269.
- 9 Powell R et al. Stent Placement in the Superficial Femoral and Proximal Popliteal Arteries with the Innova Self-Expanding Bare Metal Stent System: One-and Two-Year Results of the SuperNOVA Trial. *Catheterization and Cardiovascular Interventions* 89:1069 -1077 (2017). DOI: 10.1002/ccd.26976.
- 10 Scheinert D et al. 24-Month Results of the SUPERA SFA Registry, *J Endovasc Ther.* 2011;18:745 -752.
- 11 Matsumura JS et al. DURABILITY II 12-month results: *J Vasc Surg* 2013; 58: 73-83.
- 12 OSPREY, US Food and Drug Administration, Center for Devices and Radiological Health. Misago® RX Self-expanding Peripheral Stent P140002.
- 13 BIOFLEX-I, US Food and Drug Administration, Center for Devices and Radiological Health. Pulsar Stent Systems P160025.
- 14 Garcia L et al. Wire-Interwoven Nitinol Stent Outcome in the Superficial Femoral and Proximal Popliteal Arteries Twelve-Month Results of the SUPERB Trial. *Circ Cardiovasc Interv.* 2015;8(5). NCT00933270.
- 15 Gray M D et al. 12-month-STROLL *J Vasc Interv Radiol* 2015;26:21-28 and tctmd 2014 STROLL at 3 years.
- 16 Bosiers M et al. 4-French -Compatible Endovascular Material is Safe & Effective in the Treatment of Femoropopliteal Occlusive Disease: Results of the 4EVER Trial. *J ENDOVASC THER.* 2013; 20: 746-756.
- 17 Laird J R et al. Twelve-Month Results From the RESILIENT Randomized Trial, NCT00673985. *Circ Cardiovasc Interv.* 2010;3:267-276.
- 18 Dake M et al. Paclitaxel-Eluting Stents Show Superiority to Balloon Angioplasty and Bare Metal Stents in Femoropopliteal Disease. Twelve-Month Zilver PTX Randomized Study Results. *Circ Cardiovasc Interv.* 2011;4:495-504.
- 19 Laird J et al. Nitinol Stent Implantation in the Superficial Femoral Artery and Proximal Popliteal Artery: Twelve-Month Results From the Complete SE Multicenter Trial. *J Endovasc Ther.* 2014;21:202 -212.
- 20 Kralj I et al. Three year results of endovascular therapy with a new generation nitinol stent for femoro-popliteal artery lesions—a single-center outcome analysis of a subcohort of MISAGO 2 study. *Vasa* 2013; 42: 340-349.

Teleflex, the Teleflex logo and Pulsar are trademarks or registered trademarks of Teleflex Incorporated or its affiliates, in the U.S. and/or other countries. All other names are the trademarks or registered trademarks of their respective owners. Information in this material is not a substitute for the product Instructions for Use. Not all products may be available in all countries. Please contact your local representative.

Revised: 09/2025.

© 2025 Teleflex Incorporated. All rights reserved.

**Distributed by:**

**Teleflex Headquarters International, Ireland** · Teleflex Medical Europe Ltd. · IDA Business & Technology Park  
Dublin Road · Athlone · Co Westmeath · Tel. +353 (0)9 06 46 08 00 · Fax +353 (0)14 37 07 73 · orders.intl@teleflex.com  
**United Kingdom** Tel. +44 (0)14 94 53 27 61 · info.uk@teleflex.com  
**South Africa** Tel. +27 (0)11 807 4887 · assist.africa@teleflex.com

teleflex.com

**Teleflex™**  
Empowering the future of healthcare